Bariatric postoperative fistula: a life-saving endoscopic procedure

Giorgio Baretta, Josemberg Campos, Sércio Correia, Helga Alhinho, João Batista Marchesini, João Henrique Lima & Manoel Galvão Neto

Surgical Endoscopy
And Other Interventional Techniques
Official Journal of the Society of American Gastrointestinal and Endoscopic Surgeons (SAGES) and European Association for Endoscopic Surgery (EAES)

ISSN 0930-2794

Surg Endosc
DOI 10.1007/s00464-014-3869-z

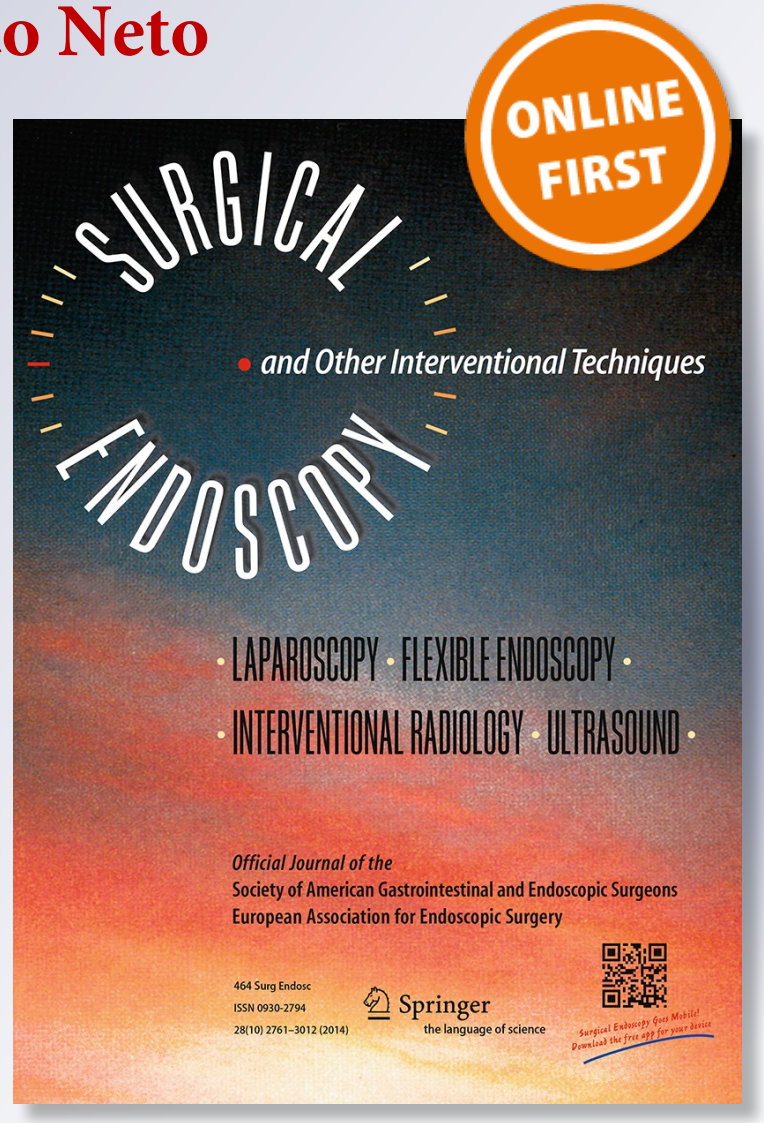

Springer

Surg Endosc
DOI 10.1007/s00464-014-3869-z

Bariatric postoperative fistula: a life-saving endoscopic procedure

Giorgio Baretta · Josemberg Campos · Sércio Correia · Helga Alhinho · João Batista Marchesini · João Henrique Lima · Manoel Galvão Neto

Received: 4 April 2014 / Accepted: 4 September 2014

Abstract
Background Gastric fistula after bariatric surgery has high morbi-mortality, and treatment is a challenge due to persistent abscess and/or distal stenosis. The present study evaluated the efficacy and safety of stricturotomy/internal drainage, a novel endoscopic procedure that can avoid re-operation and allow early oral feeding.
Methods This prospective, non-randomized study, with no control or sham group, included 27 patients (74.07 % were female), approved by the local IRB, who underwent the following bariatric surgeries: Roux-en-Y gastric bypass (RYGB; $n = 14$, 51.85 %), laparoscopic sleeve gastrectomy (LSG; $n = 9$, 33.33 %) and duodenal switch (DS; $n = 4$, 14.81 %). The patients presented with gastric fistulas which were treated by internal drainage/stricturotomy. The mean patient age was 42.67 years, and the mean pre-operative BMI was 40.69 kg/m^2. Balloon dilation was performed if distal stenosis and/or axis deviation was present. The first endoscopic procedure was applied on the 15th day after RYGB and the 30th day after LSG and DS.
Results All patients presented with His angle fistula. Eight patients (57.1 %) had stenosis of the anastomosis after RYGB and were treated with balloon dilatation (20 mm). The patients submitted to LSG and DS had stenosis at the angularis incisure and were treated with achalasia balloon dilation (30 mm). The number of endoscopic sessions for stricturotomy ranged from 1 to 6. Two patients experienced bleeding after dilation, and one had perforation. The mean time to achieve fistula closure was 18.11 days (range, 1–72 days) without mortality. All the fistulas closed.
Conclusions This novel endoscopic procedure is safe, feasible, and effective, avoiding re-operation, allowing early oral feeding and discharge.

Keywords Bariatric surgery · Postoperative fistula · Endoscopy · Stricturotomy · Internal drainage · Bariatric endoscopy

Presented at the SAGES 2014 Annual Meeting, April 2–5, 2014, Salt Lake City, Utah.

G. Baretta · J. B. Marchesini · J. H. Lima
Federal University of Parana, Curitiba, Parana, Brazil

G. Baretta (✉)
Centro Médico Hospitalar Sugisawa, Av. Iguaçú 1236, salas 112 e 113, Bairro Rebouças, Curitiba, Parana, Brazil
e-mail: giorgio.baretta@gmail.com

J. Campos · S. Correia · H. Alhinho
Department of Surgery of Federal University of Pernambuco, Recife, Pernambuco, Brazil
e-mail: josembergcampos@gmail.com

M. G. Neto
Gastro Obeso Center, São Paulo, Brazil

Despite the advantages associated with bariatric surgery, gastric fistulas are one of the most feared complications that occur after Roux-en-Y gastric bypass (RYGB), laparoscopic sleeve gastrectomy (LSG), and duodenal switch (DS). When fistulas occur after LSG, they generate more concern because of the difficulty treating them. Some of the concerning factors include distal stenosis, intra-luminal hypertension, twisted gastric pouch, and narrowing at the angularis incisure. In addition, stapling of the distal esophagus, ischemia of the His angle, super obesity, and multiple comorbidities may be involved [1]. Dehiscence of the staple line has an average occurrence of 2.4 %, and is

Published online: 08 October 2014

most common at the proximal segment just below the gastroesophageal junction [2, 3].

Difficulties in treating this complication have led to major thoracic and abdominal surgery, such as total gastrectomy, which can increase morbidity and mortality [4, 5]. Therapeutic endoscopy is a minimally invasive procedure that could be implemented to treat gastric fistula considering the increased risk of complications secondary to a surgical approach [5–8]. However, conventional endoscopic treatment of bariatric postoperative fistula is challenging due to persistent abscess and/or distal stenosis. No protocol has been established for the management of this postoperative complication, and further evaluation is needed.

The aim of this study was to evaluate the efficacy and safety of stricturotomy/internal drainage, a novel gastroscopy procedure that could avoid re-operation and allow early oral feeding and discharge.

Materials and methods

Patients

From 2009 to 2013, 27 patients with gastric fistula after RYGB ($n = 14$, 51.85 %), LSG ($n = 9$, 33.33 %), or DS ($n = 4$, 14.81 %) were referred to our hospital and included in a prospective protocol, undergoing endoscopic stricturotomy/internal drainage to treat the fistula (Tables 1, 2). All the patients presented with His angle fistula. Diagnosis was made by endoscopy, positive methylene blue test, and/or digestive secretion in the drain.

Inclusion criteria for the study were gastric fistula after bariatric surgery, age between 18 and 65 years, and the first endoscopic procedure applied 15 days after RYGB and 30 days after LSG and DS. We excluded patients with septic shock from peritonitis, gastric perforation into the peritoneal cavity without blocking, and patients using an esophageal/gastric stent. A case of gastric fistula after conversion of RYGB to DS that was treated by stricturotomy on the seventh postoperative day (POD) was also excluded.

After providing written informed consent, patients underwent endoscopic procedures to promote fistula closure. The study was approved by the IRB.

Table 1 Patient demographics

Sex, *n* (%)	
Male	7 (25.93)
Female	20 (74.07)
Age, years	
Mean	42.67
Range	22–62
BMI (Kg/m^2)	
Mean	40.69
Range	31.24–73.41

Table 2 Frequency of procedures

Type of procedure	Frequency	%
ORYGB without ring	2	7.41
LRYGB without ring	11	40.75
LRYGB with ring	1	3.70
LSG	9	33.33
ODS	2	7.41
Converted DS	1	3.70
LDS	1	3.70
Total	27	100.00

ORYGB open Roux-en-Y gastric bypass, *LRYGB* laparoscopic Roux-en-Y gastric bypass, *LSG* laparoscopic sleeve gastrectomy, *ODS* open duodenal switch, *LDS* laparoscopic duodenal switch

Therapeutic endoscopy

1 Endoscopic image of the area of the fistula (Figs. 1, 2):
   - Usually there is a perigastric cavity, a septum, and a stenosis of the distal pouch. The cavity could have variable size and can contain saliva, pus, and sometimes the drain. This cavity must be washed and cleaned with saline solution. The infected secretion must be totally aspired.

2 Stricturotomy:
   - The septum between the perigastric cavity and the gastric pouch near was incised with a Needle Knife® (Boston Scientific, Natick, MA, USA) or argon plasma coagulation, APC® (WEM, Ribeirão Preto, SP,Brazil) in order to allow communication between both cavities. The cut never exceeded the bottom of the cavity (Figs. 2 and 3).
   - A power of 50 W was used for cutting and 30 W for coagulation.
   - In other cases, APC® was used with a flow rate of 1.5 l/min and power of 40 W. We are currently using APC® due to a low risk of hemorrhage.

3. Endoscopic dilation:
   (a) In patients with RYGB:
      - The gastrojejunal anastomotic stricture was dilated up to 20 mm using a CRE® balloon

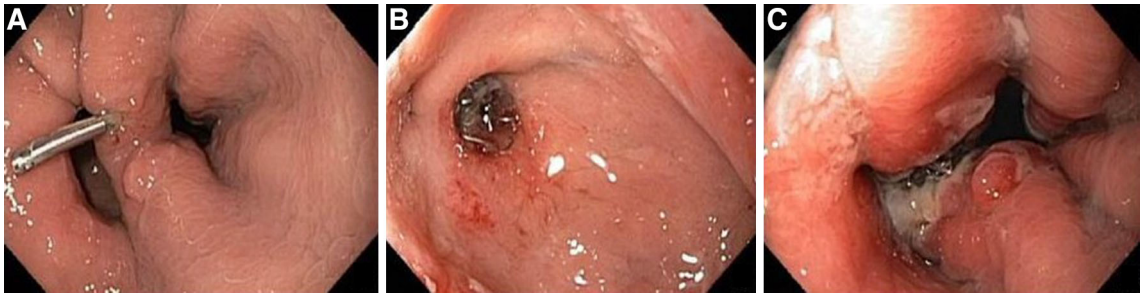

Fig. 1 **A** Septum and fistulous orifice (*left*); **B** fistula orifice; **C** enlargement of the pouch diameter after septotomy

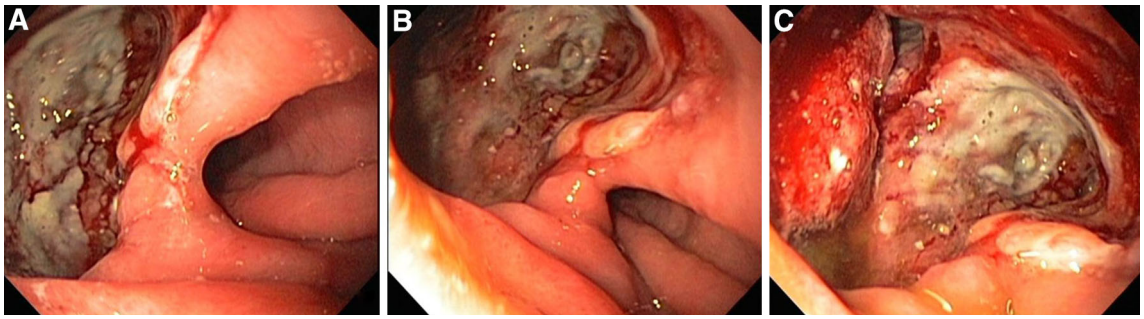

Fig. 2 **A** Great peri-pouch cavity; **B** endoscopic cleaning; **C** final aspect after septotomy

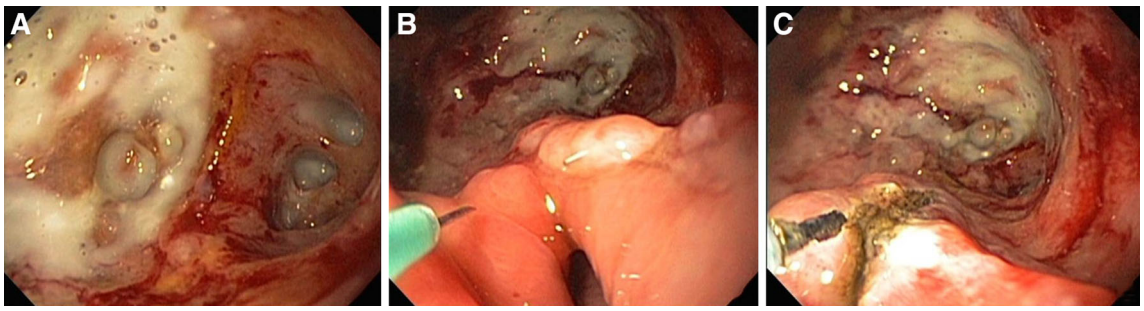

Fig. 3 **A** Partially cleaned cavity; **B** septotomy with needle-knife; **C** cut septum

(Boston Scientific, Natick, MA, USA) during 3 min.

(b) In patients with LSG and DS:

- Positioning the guide-wire Savary ® (Wilson-Cook Medical Inc., Winston Salem, NC, USA);
- Angularis incisura was dilated using a 30 mm achalasia balloon (Boston Scientific, Natick, MA, USA) during 1–3 min with a 15Psi manometer (Figs. 4 and 5);
- Endoscopic revision was performed for searching hemorrhage or perforation.

This technique allowed the internal drainage of the abscess, which led to the closure of the fistula, since the gastric outlet was restored.

All procedures were performed in the operating room under antibiotics and general anesthesia [6, 7].

Statistical analysis was performed in accordance with the nature of the data. Descriptive statistics tables were prepared containing demographic data, time to closure, pre-operative BMI, frequency of procedures, occurrence of stenosis, and dilatation. Inferential statistical tables were prepared containing time to closure and pre-operative BMI among the types of procedures, which were compared using the Mann–Whitney test. Statistical analysis of the occurrence of stenosis and dilation for the RYGB group was performed using Fisher's test, but it could not be applied for the occurrence of stenosis and dilation in the LSG and DS groups due to a lack of stenosis. Significance was set at $p < 0.05$.

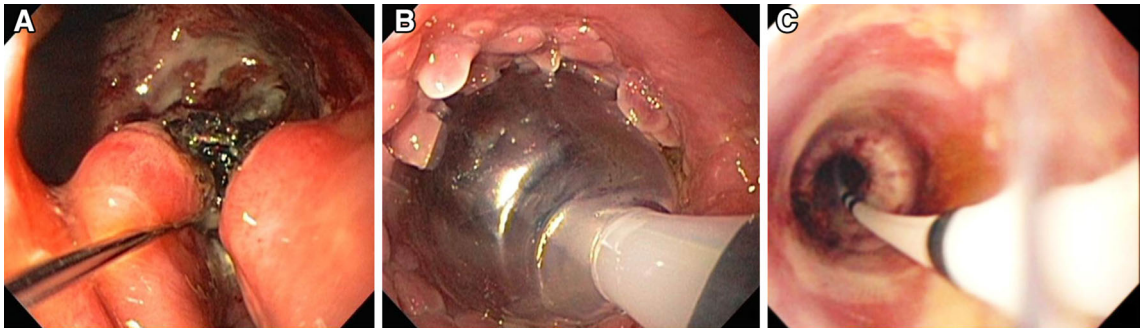

Fig. 4 Dilation procedure. **A** Guide-wire through stenosis; **B** achalasia balloon (Rigiflex by Boston®); **C** cut septum and cavity

Fig. 5 Treatment flowchart

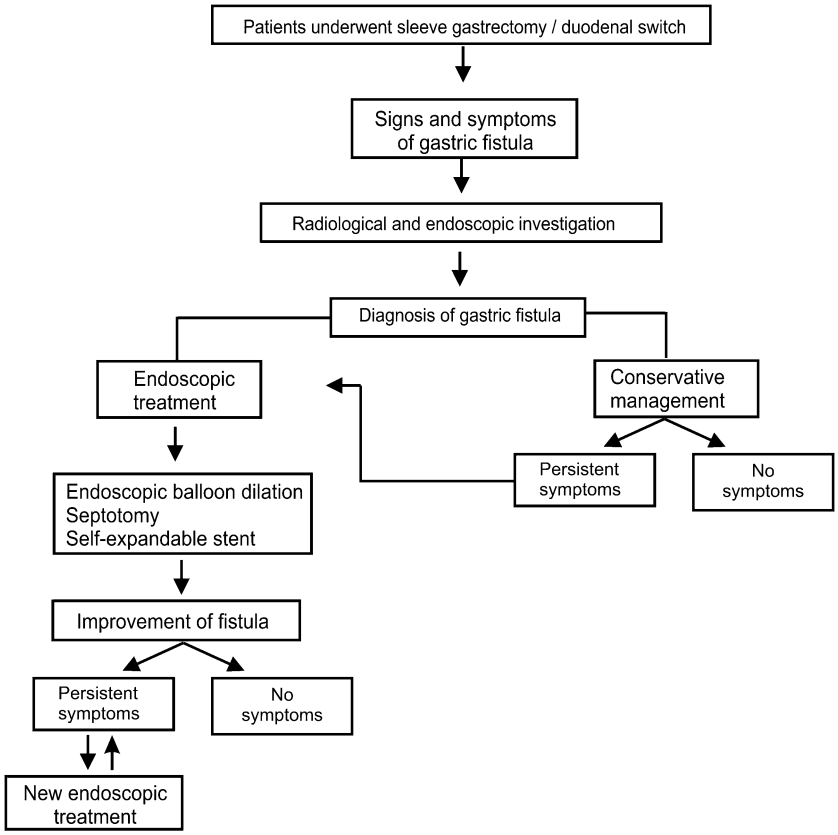

Results

The mean time between surgery and the first endoscopic procedure to treat the fistula was 217.56 days (range, 9–1825 days). The RYGB group underwent the endoscopic procedure earlier than the other groups (Table 3).

More than 78 % of the patients had stenosis at the time of endoscopy. Eight patients with RYGB (57.1 %) had stenosis of the anastomosis treated by balloon dilatation (Table 4). All the patients who underwent LSG ($n = 9$) and DS ($n = 4$) presented with angularis incisure stenosis, which was treated by Rigiflex® (Boston Scientific, Natick, MA) balloon dilation in 7 patients of the LSG group and in

Table 3 Statistical analysis of the mean time for the first endoscopic procedure (in days) between types of surgery

Type of procedure	*n*	Time for the first session				Mann–Whitney test *p*
		min–max	mean	±	dp	
RYGB	14	9–45	20.36	±	10.62	<0.0001
LSG	9	15–1,460	394.78	±	498.27	
RYGB	14	9–45	20.36	±	10.62	0.11
DS	4	12–1,825	509.00	±	880.76	
LSG	9	15–1,460	394.78	±	498.27	0.30
DS	4	12–1,825	509.00	±	880.76	

Table 4 Statistical analysis of the occurrence of stenosis and dilation in the gastric bypass group

Stenosis	Dilation		Total	Fisher's test
	Yes	No		*p*
Yes	2	6	8	0.58
No	3	3	6	
Total	5	9	14	

Table 5 Statistical analysis of the occurrence of stenosis and dilation in the sleeve gastrectomy group

Stenosis	Dilation		Total	Fisher's test
	Yes	No		*p*
Yes	7	2	9	–
No	–	–	–	
Total	7	2	9	

The test is not applicable due to the lack of stenosis

Table 6 Statistical analysis of the occurrence of stenosis and dilation in the duodenal switch group

Stenosis	Dilation		Total	Fisher's test
	Yes	No		*p*
Yes	2	2	4	–
No	–	–	–	
Total	2	2	4	

The test was not applicable due to the lack of stenosis

Table 7 Number of sessions ($n = 28$ patients)

Minimum	1
Maximum	6
Mean	1.81
Standard deviation	1.14

2 patients of the DS group (Tables 5, 6). The number of endoscopic sessions to incise the septum ranged from 1 ($n = 13$ patients) to 6 ($n = 1$ patient), with four sessions ($n = 1$), three sessions ($n = 2$), or two sessions ($n = 10$; Table 7).

Water per oral was initiated 24 h later in 22 patients. Four patients sustained nutritional support via a nasogastric tube in the beginning of our experience, and one patient underwent laparoscopy. Regarding complications after the endoscopic procedures, one RYGB patient experienced bleeding after endoscopic dilatation; epinephrine was locally injected. Another case undergoing DS was treated by local injection of epinephrine for the bleeding in the dilated area. One patient had a 35-mm perforation of the gastric body after dilation with Rigiflex® (Boston Scientific, Natick, MA) post-LSG; laparoscopy, and abdominal drainage were performed as well as jejunostomy for feeding. Two RYGB patients, one LSG and one DS patient in the beginning of our study sustained enteral nutritional support via nasogastric tube due to our lack of experience with this kind of endoscopic procedure—stricturotomy.

Table 8 Time to closure (in days, $n = 28$ patients)

Minimum	1
Maximum	72
Mean	18.11
Standard deviation	18.93

Table 9 Statistical analysis of closing time between types of surgery

Type of surgery	*n*	Closing time (days)				Mann–Whitney test
		Min–max	Mean	±	dp	*p*
RYGB	14	1–49	9.57	±	12.26	<0.01
LSG	9	3–72	24.67	±	23.46	
RYGB	14	1–49	9.57	±	12.26	<0.001
DS	4	15–45	33.25	±	14.57	
LSG	9	3–72	24.67	±	23.46	0.20
DS	4	15–45	33.25	±	14.57	

Patients who ingested liquid and no longer had any debt secretion by cutaneous fistula orifice were considered treated. The time to closure ranged from 1 to 72 days (Table 8). RYGB had faster resolution of the fistula with endoscopic treatment compared to LSG and DS (Table 9). All the fistulas closed.

Discussion

According to a systematic review by Aurora et al. [2], 92 % of fistulas after LSG occur near the esophagogastric junction, although only 50 % of studies reported their location. In the present study, all fistulas occurred at the angle of His. Usually the patient shows signs and symptoms of infection [9] and high levels of C-reactive protein [10]. In this study, patients in the RYGB group and three patients in the DS group had their fistulas diagnosed by a positive methylene blue test. The fourth patient from the DS group had late-onset fistula with a fistulous orifice and fetid discharge in the left upper quadrant. Three of the LSG had drainage in the left upper quadrant, and the rest underwent surgical drainage in other hospitals. In all cases the diagnosis was confirmed by endoscopy. X-ray contrast is not routinely performed at our institution, but it helps to

define the anatomy of the gastric pouch when it is performed, assessing all of the areas of deviation and/or distal stenosis [6, 8, 11].

After diagnosis, some therapeutic measures should be instituted, including discontinuation of oral diet, nutritional support, use of broad spectrum antibiotics, and proton pump inhibitors [12]. In addition, surgical and/or endoscopic procedures should be performed to control sepsis and close the fistula. Re-operations in patients with gastric fistulas are accompanied by high morbidity and mortality. Thus, we adopted the endoscopic treatment of this complication, resulting in therapeutic success with low morbidity and no mortality in most cases.

Stents were not used in this study, as the treatment was delayed and the benefits in this context are not proven [13, 14]. Stents should be used for early onset fistulas without fibrosis [13]. The treatment proposed in this study was based on minimally invasive techniques using endoscopic approaches, preserving surgery for exceptional cases in which the fistulas could not be treated percutaneously. Thus, surgery is presented as an alternative for treating complications of the fistula and not as therapeutic for the closure of the fistula so long as it does not interfere in its pathogenesis.

Campos et al. published the first case of stricturotomy and dilation for treating a chronic gastrobronchial fistula after bariatric surgery [11]. The idea came from the endoscopic treatment for Zencker diverticulum [15], which achieves the following results: internal drainage of the perigastric abscess, stops contamination of the abdominal cavity by directing digestive secretion, ensures adequate patency of the gastric lumen, and decreased intragastric pressure.

In the first five patients, we used electrocautery, but there was bleeding. Therefore, we opted to use APC. Electrocautery is currently reserved for chronic cases with severe fibrosis.

Balloon dilation promotes a wider communication between the gastric pouch and fibrotic cavity parallel to the pouch, allowing food residues and digestive secretions to follow the usual path of the gastric lumen without a dam, enabling the treatment of local infections and abscesses, and triggering the healing of granulation tissue and closure of the fistula. This is important because, in cases where the abscess is not drained, the inflammatory response is perpetuated and does not allow healing of the fistula.

The number of stricturotomy and achalasia balloon dilation sessions ranged from 1 to 6, with an average of less than two sessions, which provided rapid closure of the fistula; rather, rapid resolution of the signs and symptoms of the fistula (average 18.11 days) with earlier hospital discharge than reported in the literature [1, 16].

Accurate diagnosis and a minimally invasive approach through endoscopy, with the combination of dilation and stricturotomy, had a high success rate, despite the small sample. Endoscopic treatment enabled early control of the gastric fistula, reducing the need for re-laparotomy and early outpatient treatment, with reduced length of hospital stays. The healing of the gastric fistula is mainly because of the healing of the distal stenosis, decreasing the intraluminal pressure and controlling local changes that precluded healing, such as abscesses and infections [6]. Therefore, this novel endoscopic procedure is safe, feasible, and effective, avoiding re-operations and allowing early oral feeding without mortality.

Disclosures Drs. Giorgio A. P. Baretta, Josemberg M. Campos, Helga C. A. W. Alhinho, Sércio F. B. M. Correia, João Batista Marchesini, João Henrique F. de Lima, Manoel Galvão P. Neto have no conflicts of interest or financial ties to disclose.

References

1. Serra C, Baltasar A, Perez N, Bou R, Bengochea M (2006) Total gastrectomy for complications of the duodenal switch, with reversal. Obes Surg 16:1082–1086
2. Aurora AR, Khaitan L, Saber AA (2012) Sleeve gastrectomy and the risk of leak: a systematic analysis of 4,888 patients. Surg Endosc 26:1509–1515
3. Hutter MM, Schirmer BD, Jones DB, Ko CY, Cohen ME, Merkow RP, Nguyen NT (2011) First report from the American College of Surgeons Bariatric Surgery Center Network: laparoscopic sleeve gastrectomy has morbidity and effectiveness positioned between the band and the bypass. Ann Surg 254:410–420 discussion 420-412
4. Casella G, Soricelli E, Rizzello M, Trentino P, Fiocca F, Fantini A, Salvatori FM, Basso N (2009) Nonsurgical treatment of staple line leaks after laparoscopic sleeve gastrectomy. Obes Surg 19:821–826
5. Vilallonga R, Himpens J, van de Vrande S (2013) Laparoscopic management of persistent strictures after laparoscopic sleeve gastrectomy. Obes Surg 23:1655–1661
6. Campos JM, Pereira EF, Evangelista LF, Siqueira L, Neto MG, Dib V, Falcao M, Arantes V, Awruch D, Albuquerque W, Ettinger J, Ramos A, Ferraz A (2011) Gastrobronchial fistula after sleeve gastrectomy and gastric bypass: endoscopic management and prevention. Obes Surg 21:1520–1529
7. Zundel N, Hernandez JD, Galvao Neto M, Campos J (2010) Strictures after laparoscopic sleeve gastrectomy. Surg Laparosc Endosc Percutan Tech 20:154–158
8. Campos JM, Siqueira LT, Meira MR, Ferraz AA, Ferraz EM, Guimaraes MJ (2007) Gastrobronchial fistula as a rare complication of gastroplasty for obesity: a report of two cases. J Bras Pneumol 33:475–479
9. Csendes A, Burgos AM, Burdiles P (2009) Incidence of anastomotic strictures after gastric bypass: a prospective consecutive routine endoscopic study 1 month and 17 months after surgery in 441 patients with morbid obesity. Obes Surg 19:269–273
10. Jurowich C, Thalheimer A, Seyfried F, Fein M, Bender G, Germer CT, Wichelmann C (2011) Gastric leakage after sleeve

gastrectomy-clinical presentation and therapeutic options. Langenbecks Arch Surg 396:981–987
11. Campos JM, Siqueira LT, Ferraz AA, Ferraz EM (2007) Gastrobronchial fistula after obesity surgery. J Am Coll Surg 204:711
12. Papavramidis TS, Kotzampassi K, Kotidis E, Eleftheriadis EE, Papavramidis ST (2008) Endoscopic fibrin sealing of gastrocutaneous fistulas after sleeve gastrectomy and biliopancreatic diversion with duodenal switch. J Gastroenterol Hepatol 23:1802–1805
13. Simon F, Siciliano I, Gillet A, Castel B, Coffin B, Msika S (2013) Gastric leak after laparoscopic sleeve gastrectomy: early covered self-expandable stent reduces healing time. Obes Surg 23: 687–692
14. Rosenthal RJ, Diaz AA, Arvidsson D, Baker RS, Basso N, Bellanger D, Boza C, El Mourad H, France M, Gagner M, Galvao-Neto M, Higa KD, Himpens J, Hutchinson CM, Jacobs M, Jorgensen JO, Jossart G, Lakdawala M, Nguyen NT, Nocca D, Prager G, Pomp A, Ramos AC, Shah S, Vix M, Wittgrove A, Zundel N (2012) International sleeve gastrectomy expert panel consensus statement: best practice guidelines based on experience of >12,000 cases. Surg Obes Relat Dis 8:8–19
15. Adams J, Sheppard B, Andersen P, Myers B, Deveney C, Everts E, Cohen J (2001) Zenker's diverticulostomy with cricopharyngeal myotomy: the endoscopic approach. Surg Endosc 15:34–37
16. Puli SR, Spofford IS, Thompson CC (2012) Use of self-expandable stents in the treatment of bariatric surgery leaks: a systematic review and meta-analysis. Gastrointest Endosc 75:287–293